

Key Insights On The Percutaneous Calcaneal Displacement Osteotomy

In contrast to a lateral open osteotomy, the percutaneous calcaneal displacement osteotomy facilitates less soft tissue and neurovascular compromise, a reduced risk of post-op wound complications and improved cosmesis. With this in mind, these authors take a closer look at the literature on the technique and offer a practical guide to performing the osteotomy.

*By Lawrence A. DiDomenico, DPM, FACFAS,
Zach Flynn, DPM, and Adam Grahn, DPM*

The posterior calcaneal displacement osteotomy is an established and reliable procedure, which surgeons often use in conjunction with other procedures to correct hindfoot deformities.^{1,2} These deformities include calcaneal valgus, posterior tibial tendon dysfunction, flexible flatfoot deformity, calcaneal varus, lateral ankle instability and loss of calcaneal height after calcaneal fracture. Complications associated with the standard open lateral approach include wound dehiscence, sural nerve damage or neuritis, delayed union, non-union, infection, and invasion of the medial neurovascular structures.^{3,4} The emergence of the percutaneous calcaneal displacement osteotomy enables surgeons to avoid these complications.

We perform this technique through four small stab incisions in order to avoid making a large incision through the thin lateral soft tissue layers as well as major neurovascular structures, which would normally be at risk when exiting medially in the traditional open osteotomy.⁵ The indications for the percutaneous technique are the same as those for the open osteotomy and there are no contraindications to the percutaneous technique versus the open osteotomy.^{1,2}

The advantages of the percutaneous calcaneal displacement osteotomy are the following: less stress and trauma to the bone and soft tissues, and less blood loss. The technique:

- minimizes the risk of postoperative wound problems and infection;

- provides faster rehabilitation and mobilization (if the surgeon performs this osteotomy as an isolated procedure);
- decreases time to achieve union;
- facilitates better cosmesis; and
- has fewer neurovascular complications in comparison to an open osteotomy.

A Closer Look At The Percutaneous Technique: What Does The Literature Reveal?

The traditional lateral incision for the open calcaneal displacement osteotomy has been associated with wound complications in 5 to 10 percent of patients and sural nerve damage is associated with 7 to 25 percent of patients.^{6,7} In recent years, numerous surgeons have developed various percuta-

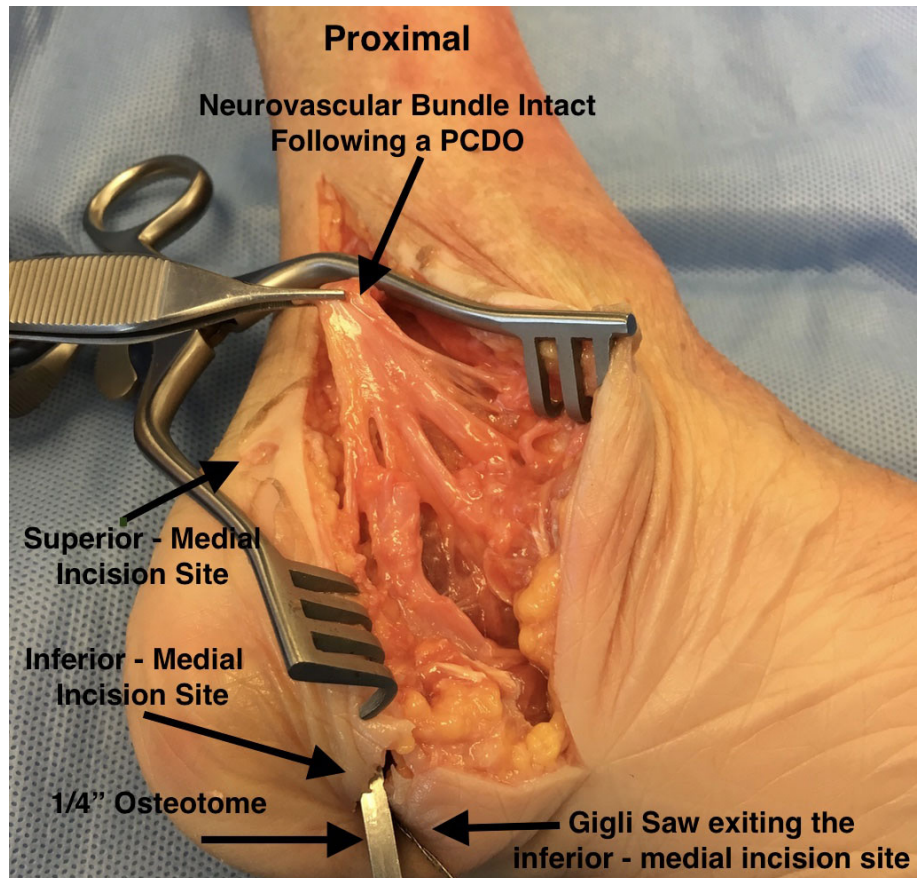
neous or minimally invasive techniques to perform the calcaneal osteotomy in an effort to minimize these complications. Additionally, cadaveric studies have illustrated how these techniques protect the vital neurovascular structures and retrospective cohort studies and case series have shown good clinical outcomes.

In 2004, Mendicino and colleagues described one of the original percutaneous techniques using one small lateral incision through which the surgeon starts the osteotomy with multiple drill holes across the calcaneus and finishes with an osteotome.⁸ The study reported no cadaveric or clinical results, but the authors commented that the technique minimizes soft tissue and periosteal dissection and should help healing.

The technique we describe here, and which the senior author first reported in 2004, entails the surgeon passing a flexible Gigli saw through a subperiosteal tunnel around the calcaneus using four stab incisions, two on each side of the heel.⁵ A follow-up study on 20 cadaveric limbs revealed no iatrogenic injury to the sural nerve, medial and lateral plantar nerves, or posterior tibial nerve, artery, and vein in any of the specimens.⁹ Clinical evaluation of over 100 procedures revealed four patients with transient lateral neuritis symptoms, all of which resolved after 10 to 12 weeks.

In 2013, Tennant and coworkers described a modification to the Gigli saw technique.¹⁰ In their “percutaneous endoscopically-assisted calcaneal osteotomy,” one first passes a suture through three stab incisions (two lateral and one proximal medial) with arthroscopic guidance, and then uses the suture to shuttle the Gigli saw around the calcaneus. Out of 25 patients with an average follow-up of eight months, no patients had vascular or wound complications, but one had numbness in the sural nerve distribution postoperatively. In a recent follow-up study, the authors found damage to one of 11 lateral calcaneal nerve branches in eight cadaveric specimens after percutaneous endoscopically-assisted calcaneal osteotomy.¹¹ This is in comparison to eight of 10 branches that potentially would have been damaged using the traditional open technique.

Since 2015, several studies have described variations of a new minimally



This is a cadaver dissection of the medial ankle/foot following a percutaneous calcaneus displacement osteotomy. Note the posterior tibial nerve, medial plantar nerve, lateral plantar nerve and the medial calcaneal nerve are without injury. Note the location of the 1/4 inch osteotome and the Gigli saw are inferior and posterior to the nerve bundle.

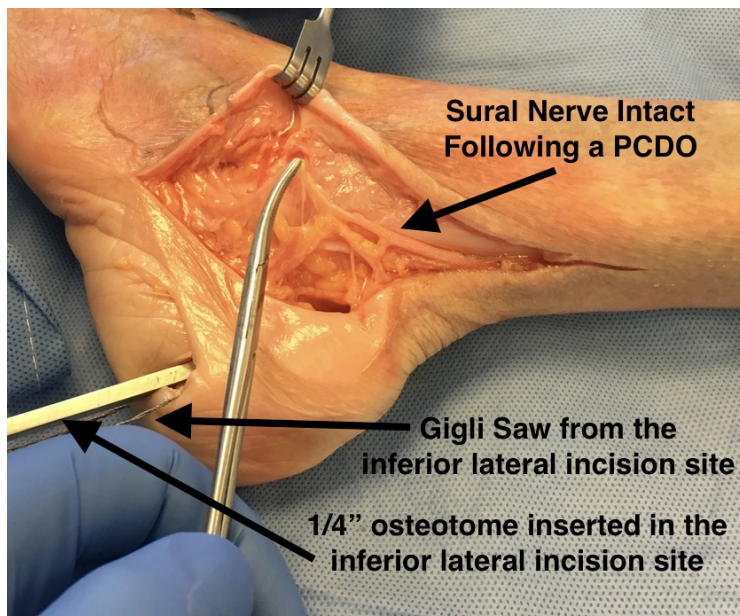
invasive technique using a low speed, high torque straight or Shannon burr in a rotational sweeping motion to perform the calcaneal osteotomy through a single small lateral incision.^{6,7,12,14-16}

Kendal and colleagues published a retrospective cohort study comparing complications of this percutaneous technique with the traditional open lateral approach.⁶ Eighty-one patients were included over a six-year period, 50 in the open approach group and 31 in the percutaneous group. While calcaneal displacement, fusion rate and short-term clinical outcomes were similar between the two groups, there were significantly fewer wound complications in the percutaneous group in comparison to the open group (6.45 versus 28 percent), and the infection rate of these wounds was also lower in the percutaneous group (3 versus 20 percent). Also, sural nerve damage occurred in 6 percent of the open group

versus none in the percutaneous group.

In a review of 30 cases involving the use of minimally invasive calcaneal osteotomies, Kheir and colleagues reported no neurovascular or wound complications.¹² Similarly, Jowett and coworkers reported a 100 percent fusion rate with no neurovascular injury or wound complications in 35 cases of minimally invasive calcaneal osteotomies.⁷ They also performed the osteotomy on nine cadaveric specimens and found no injury to any neurovascular structures.

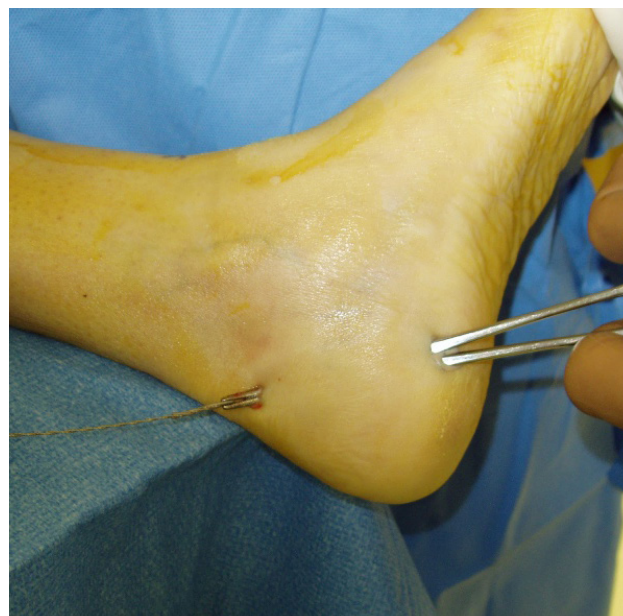In a cadaveric study of 20 limbs comparing an open approach versus a percutaneous burr technique, Talusan and coworkers found damage to the lateral calcaneal nerve in three of 10 open procedures and one of 10 percutaneous procedures as well as damage to the medial calcaneal nerve in three of 10 open procedures and two of 10 percutaneous procedures.¹³ None of the specimens had damage to the sural,



Sural Nerve Intact Following a PCDO

Gigli Saw from the inferior lateral incision site

1/4" osteotome inserted in the inferior lateral incision site



This photo demonstrates the tonsil stat grasping the Gigli saw from the superior medial incision and preparing to pull the Gigli saw through the inferior medial incision.

This is a cadaver dissection of the lateral ankle/foot following a percutaneous calcaneus displacement osteotomy. Note the sural nerve is unharmed.

medial plantar or lateral plantar nerves in either procedure.

Another cadaveric study by Durston and colleagues only found damage to one lateral calcaneal nerve branch in two of 13 specimens following the percutaneous burr technique.¹⁴ In both of those specimens, another undamaged lateral calcaneal branch was present.

Lui and colleagues described a technique using a combination of two crossing drill holes across the calcaneus and a straight burr to perform the percutaneous osteotomy.¹⁵ They reported good outcomes and no complications in 11 patients.

The recent emergence of a soft tissue preserving metal jig provides the surgeon with accurate alignment and stabilization of the Shannon burr with a fixed center of rotation while performing the osteotomy.¹ In a review of minimally invasive calcaneal osteotomies, Guyton reported on his personal series of 73 surgeries, 48 of which he performed after the development of the guiding jig.¹ The author had no cases of non-union but delayed wound healing occurred in seven patients.

If a surgeon does not have access to this designed jig, Lee and coworkers described their technique of using a Kirschner wire introduced subcutaneously along the surface of the calcaneus running parallel to the osteotomy.¹⁶

A Quick Guide To The Instrumentation

The instrumentation a surgeon would use to perform the percutaneous calcaneal displacement osteotomy consists of a large and small curved hemostat, a large and small straight hemostat, a tonsil stat, 1/4 inch osteotome, a #15 blade and Bard Parker handle, a Gigli saw, and Gigli saw handles.

Our experience is that the Gigli saw needs to be as flexible as possible in order to avoid kinks in the saw, particularly when going around the medial superior and lateral superior edges of the calcaneus. In our experience, the Gigli saw that works best to perform this osteotomy is the 12 inch Gigli saw made by DePuy.

How To Perform The Percutaneous Technique

Our technique for the percutaneous technique involves four incisions, two on the lateral aspect of the heel and two on the medial aspect of the heel. The plantar medial incision is oblique in the line of the osteotomy and distal to the plantar medial tubercle. This incision placement is inferior and posterior to the neurovascular bundle medially.

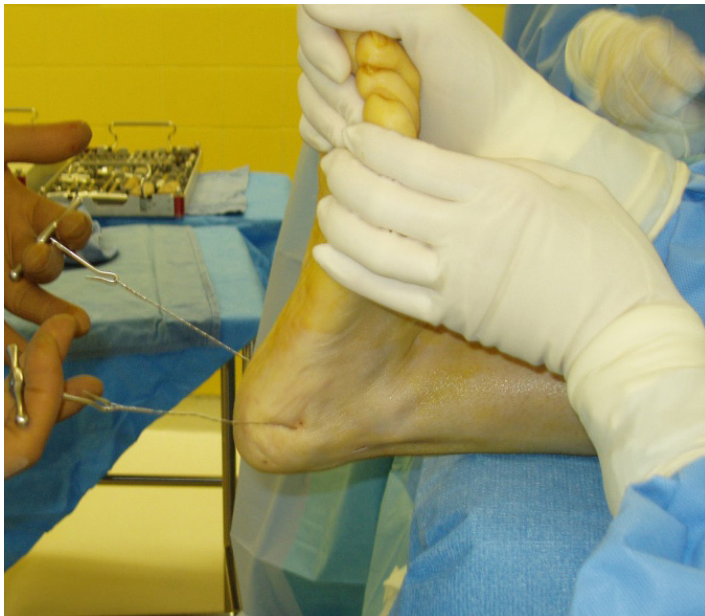Using the curved hemostat, bluntly deepen the incision down to bone. With the curved end of the hemostat pointing

toward the skin, proceed to make a tunnel toward the superior aspect of the calcaneus. Ensure the tunnel is deep to all of the neurovascular structures and keep the hemostat against the bone. This is imperative to avoid capturing any of the soft tissue structures within your cut. As Greene and colleagues demonstrated in their study, various soft tissue structures can be compromised without careful planning during the traditional open approach.²

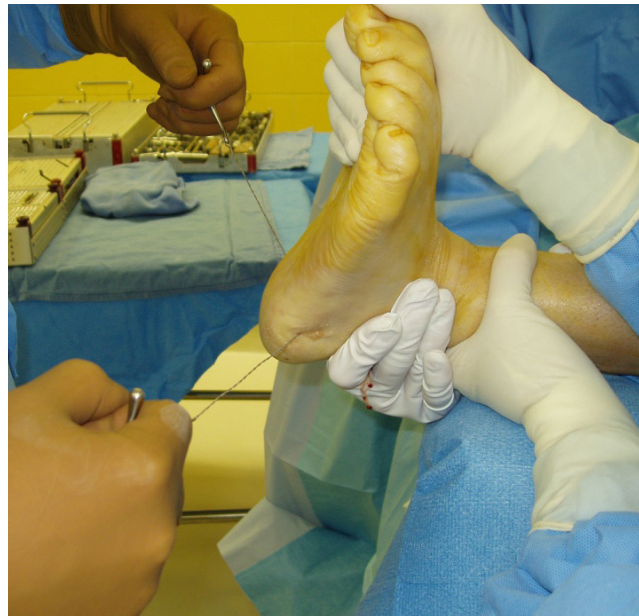Tent the skin at the superior medial aspect of the calcaneus with the hemostat. Make a stab incision along the resting skin tension lines. The tip of the curved hemostat exits the incision site. This is the site where one will introduce the Gigli saw. Open the tip of the hemostat and clamp one end of the Gigli saw. Pull the hemostat inferiorly through the tunnel and through the inferior medial incision. One loop of the Gigli saw is now exiting the medial inferior incision. Unclamp the hemostat from the end of the Gigli saw.

Redirect attention back to the superior medial incision. Using the straight hemostat, bluntly tunnel across the superior aspect of the calcaneus. Make this tunnel anterior to the Achilles tendon and posterior to the posterior facet of the calcaneus in Kager's triangle. Be sure to keep the hemostat on the superior aspect of the calcaneus while tunneling across. Tent the skin

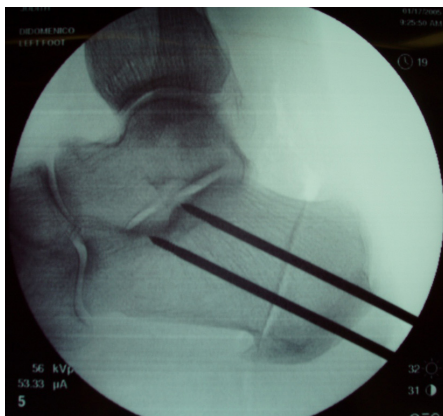
Osteotomy



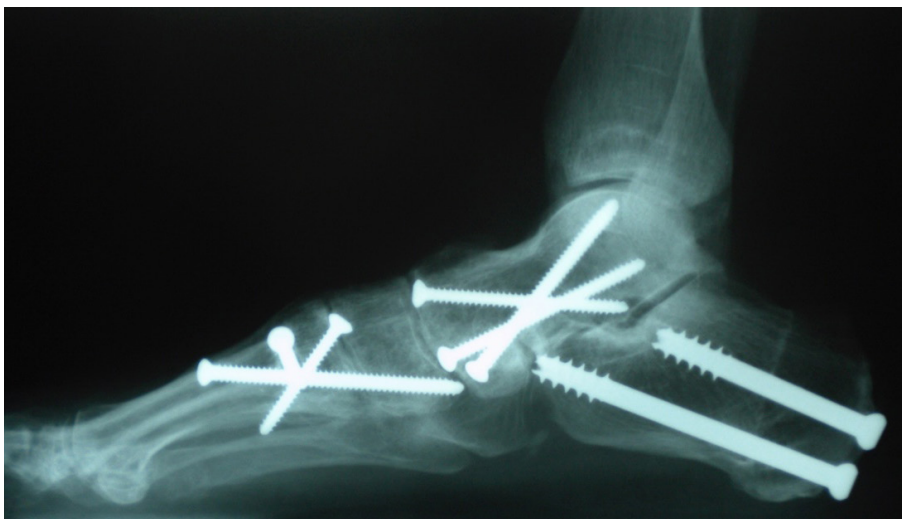After completing the Gigli saw dissection, the assistant should dorsiflex the ankle and toes, and stabilize the hindfoot and ankle. The surgeon should pull on the Gigli saw with tension along the medial and lateral walls of the calcaneus.



This is a photo taken near the completion of the osteotomy. Note the surgeon's arms have gotten wider relative to his/her body as the Gigli saw is now becoming straight/linear as it approached the plantar cortex.



This intraoperative lateral radiograph demonstrates the completion of a percutaneous calcaneus displacement osteotomy in an adult with two guide wires stabilizing the osteotomy in preparation for insertion of two large cannulated cancellous screws.



This is a post-op lateral radiograph demonstrating good anatomic alignment and good fixation after a percutaneous calcaneus displacement osteotomy, talar navicular arthrodesis and a Lapidus bunionectomy.

laterally and make a stab incision posterior to the peroneal tendons and sural nerve.

Remove the hemostat from the medial superior site and introduce the small straight hemostat from the superior lateral incision. Follow the tunnel and exit the superior medial incision site. Open the tips of the hemostat and place the free end of the Gigli saw into the tip. Clamp down and pull the hemostat and Gigli saw through the tunnel from superior medial to superior or lateral. Exit the superior lateral incision,

pulling the end of the Gigli saw through the incision.

Make the fourth stab incision at the lateral inferior location of the calcaneus. Once again, make a tunnel toward the superior lateral incision. Be sure to keep the tip of the hemostat against the body of the calcaneus. This tunnel will be deep to the neurovascular structures. Exit the superior lateral incision and open the tip of the hemostat. Insert the free loop of the Gigli saw into the tip of the curved

hemostat. Pull the hemostat back through the tunnel and out the lateral inferior incision. The Gigli saw should now be taut to the calcaneus and deep to all neurovascular structures along the medial and lateral body of the calcaneus.

Using fluoroscopy, take a lateral view of the foot, checking to ensure there are no kinks in the saw and that the saw is in the desired placement. The placement of the incisions ensures that one performs the osteotomy in the proper plane, which

should have a posterior inclination at approximately 45 degrees to the plantar surface of the rearfoot.

Prior to cutting, the foot should be in dorsiflexion with the windlass mechanism activated to allow soft stability of the hindfoot. The assistant should also stabilize the leg. Perform cutting swiftly and gradually widen your hands/arms as they move plantar to perform an even cut and protect the soft tissue. Prior to the osteotomy, loop the Gigli saw loops around the calcaneus superiorly and exit out the medial and lateral inferior incision sites. As one performs the osteotomy, the Gigli saw is no longer looped around the calcaneus. As the saw penetrates through the calcaneus, the Gigli saw becomes more linear. The surgeon's pull goes from a pull along his or her arms close to the body to wide as the Gigli saw goes from superior calcaneus to inferior calcaneus in order to avoid harming the soft tissues around the inferior medial and lateral incision sites. One must take care to feel the plantar cortex as soft tissue structures plantar to the calcaneus could be violated.

Upon completion of the cut, cut one end of the Gigli saw with wire cutters, allowing easy removal. While positioning the posterior fragment, have the assistant plantarflex the foot. This will loosen the windlass mechanism and allow manipulation and final positioning. Once the osteotomy is in the desired position, dorsiflex the foot and ankle to tighten the soft tissues and maintain the correction until placing final hardware across the osteotomy.

Other Clinical Indications And Considerations With The Percutaneous Calcaneal Displacement Osteotomy

Many authors have described the use of the calcaneal displacement osteotomy in addressing a flexible flatfoot deformity.¹⁷ By shifting the posterior fragment medially, one realigns the pull of the Achilles complex, inducing a more supinatory pull. Then follow with other ancillary procedures such as an Evans osteotomy and medial column procedure.

Surgeons can use the osteotomy for varus deformities such as the cavovarus foot. This patient group includes patients with chronic lateral ankle instability with a varus position of the hindfoot. For these

patients, one pushes the posterior fragment laterally, inducing more of a pronatory pull and alleviating the stress on the lateral ligament complex.

Additionally, the surgeon has the option to shift the posterior segment either plantarly or dorsally. In cases of the flexible flatfoot or previous calcaneal fracture, shifting the posterior fragment plantarly can help restore the calcaneal inclination and overall height of the hindfoot. In those cases of high calcaneal pitch and cavovarus foot type, the surgeon may shift the posterior segment dorsally to reduce the pitch and yield more correction.

In Conclusion

Overall, the indications for the open or percutaneous calcaneal displacement osteotomy are identical. It is our experience that the percutaneous technique has yielded better cosmesis, less soft tissue compromise, lower risk of neurovascular compromise and a smoother osteotomy, allowing easy intraoperative manipulation and positioning. Exercising caution with saw placement will avoid any potential risk to the soft tissues. We also recommend using a flexible Gigli saw, which aids with saw placement as this can be tedious with less forgiving saws. If the percutaneous technique fails or the surgeon encounters issues, connection of the lateral stab incisions allows easy conversion to an open approach. ■

Dr. DiDomenico is in private practice at Ankle and Foot Care Centers in Youngstown, Ohio. He is the Section Chief of the Department of Podiatry at St. Elizabeth Hospital in Youngstown, Ohio. Dr. DiDomenico is also the Director of Fellowship Training of the Reconstructive Rearfoot and Ankle Surgical Fellowship and Residency Training at Northside Hospital in Youngstown, Ohio. He is a faculty member of Heritage Valley Health Systems in Beaver, Pa. Dr. DiDomenico is a Fellow of the American College of Foot and Ankle Surgeons.

Dr. Flynn is in private practice at Ankle and Foot Care Centers in Youngstown, Ohio.

Dr. Grahn is a second-year resident at Northside Hospital in Youngstown, Ohio.

References

1. Guyton GP. Minimally invasive osteotomies of the calcaneus. *Foot Ankle Clin*. 2016 Sep;21(3):551-66.
2. DiDomenico LA, Anain J, LaCivita MD. Per-

cutaneous calcaneal displacement osteotomy. In Maffuli N, Easley M (eds.): *Minimally Invasive Surgery of the Foot and Ankle*. Springer, New York, 2011, pp. 231-244.

3. Frankel J, Turf RM, Nichols D. Complications of calcaneal osteotomies. *Clin Podiatric Med Surg*. 1991;8(2):409-423.
4. Greene DL, Thompson MC, Gesink DS, Graves SC. Anatomic study of the medial neurovascular structures in relation to calcaneal osteotomy. *Foot Ankle Int*. 2001;22(7):569-571.
5. Dull JM, DiDomenico LA. Percutaneous displacement calcaneal osteotomy. *J Foot Ankle Surg*. 2004;43(5):336-7.
6. Kendal AR, Khalid A, Ball T, Rogers M, Cooke P, Sharp R. Complications of minimally invasive calcaneal osteotomy versus open osteotomy. *Foot Ankle Int*. 2015;36(6):685-90.
7. Jowett CR, Rodda D, Amin A, Bradshaw A, Bedi HS. Minimally invasive calcaneal osteotomy: A cadaveric and clinical evaluation. *Foot Ankle Surg*. 2016;22(4):244-247.
8. Mendicino RW, Catanzariti AR, Reeves CL. Posterior calcaneal displacement osteotomy: a new percutaneous technique. *J Foot Ankle Surg*. 2004;43(5):332-5.
9. DiDomenico LA, Anain J, Wargo-Dorsey M. Assessment of medial and lateral neurovascular structures after percutaneous posterior calcaneal displacement osteotomy: a cadaver study. *J Foot Ankle Surg*. 2011;50(6):668-71.
10. Tennant JN, Veljkovic A, Phisitkul P. Technique tip: percutaneous endoscopically-assisted calcaneal slide osteotomy. *Iowa Orthop J*. 2013;33:191-5.
11. Veljkovic A, Tennant J, Rungprai C, Abbas KZ, Phisitkul P. An anatomic study of the percutaneous endoscopically assisted calcaneal osteotomy technique to correct hindfoot malalignment. *Foot Ankle Int*. 2017;38(2):192-199.
12. Kheir E, Borse V, Sharpe J, Lavalette D, Farnodon M. Medial displacement calcaneal osteotomy using minimally invasive technique. *Foot Ankle Int*. 2015;36(3):248-52.
13. Talusan PG, Cata E, Tan EW, Parks BG, Guyton GP. Safe zone for neural structures in medial displacement calcaneal osteotomy: a cadaveric and radiographic investigation. *Foot Ankle Int*. 2015;36(12):1493-8.
14. Durston A, Bahoo R, Kadambande S, Hariharan K, Mason L. Minimally Invasive Calcaneal Osteotomy: Does the Shannon burr endanger the neurovascular structures? A cadaveric study. *J Foot Ankle Surg*. 2015;54(6):1062-6.
15. Lui TH. Percutaneous posterior calcaneal osteotomy. *J Foot Ankle Surg*. 2015;54(6):1188-92.
16. Lee M, Guyton GP, Zahoor T, Schon LC. Minimally invasive calcaneal displacement osteotomy site using a reference Kirschner wire: a technique tip. *J Foot Ankle Surg*. 2016;55(5):1121-6.
17. Trnka HJ, Easley ME, Myerson MS. The role of calcaneal osteotomies for correction of adult flatfoot. *Clin Orthop Relat Res*. 1999; 365:50-64.